

Candidate No: _____



The Hong Kong College of Anaesthesiologists

Final Fellowship Examinations

Paper II – Radiology

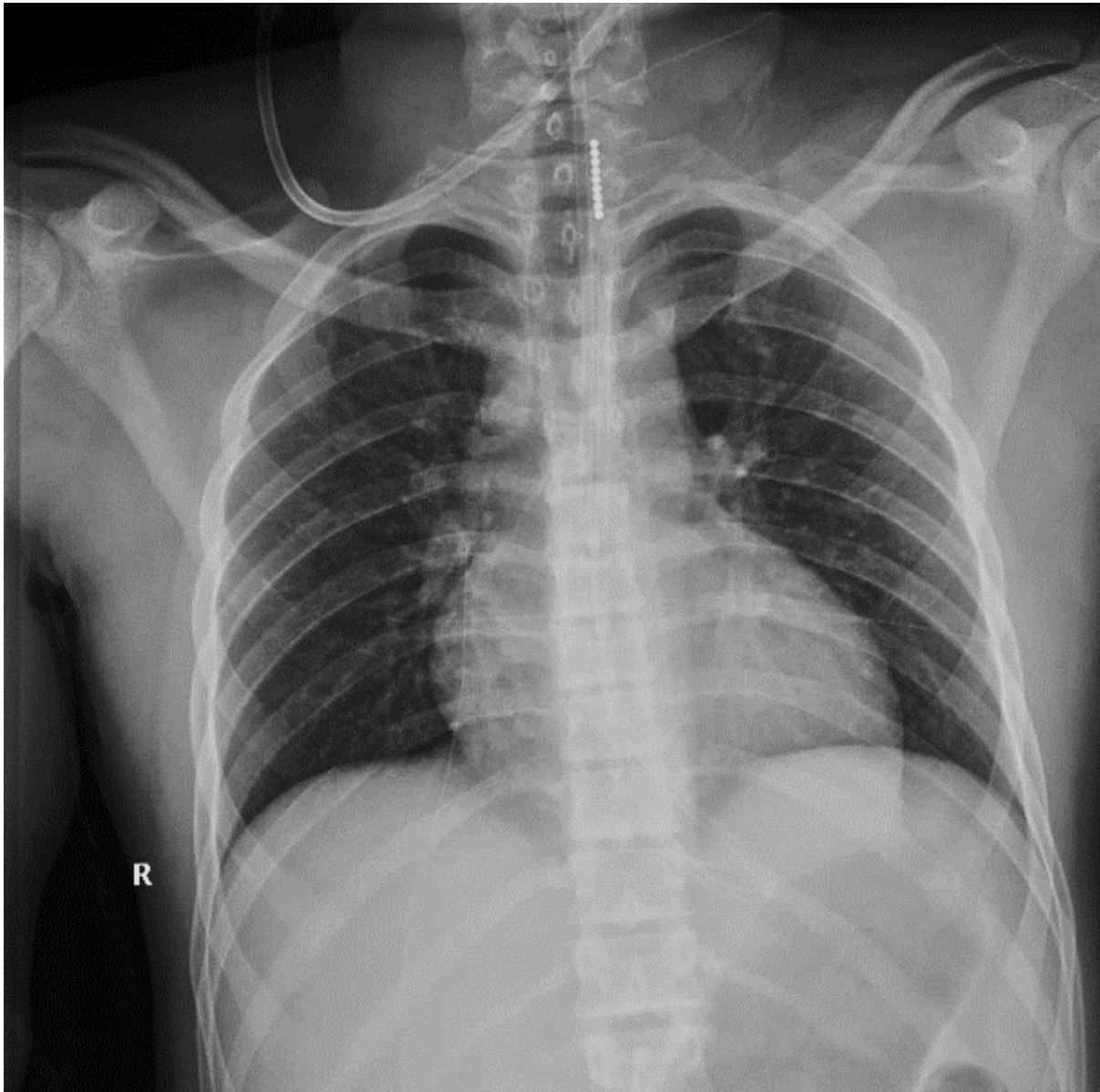17 March 2025 (Monday)

12:40 – 12:50 hours

Instructions:

- a. This is a question-answer book. Please write your answers in the space provided.
- b. Write your candidate number on the first page of the answer book.
- c. Use ink or ball-point pen.
- d. There are 5 questions in this paper, each with multiple parts.
- e. Answer **ALL** questions.
- f. For questions with multiple parts, allocation of marks is indicated in the brackets.

Question 1 (6 marks)

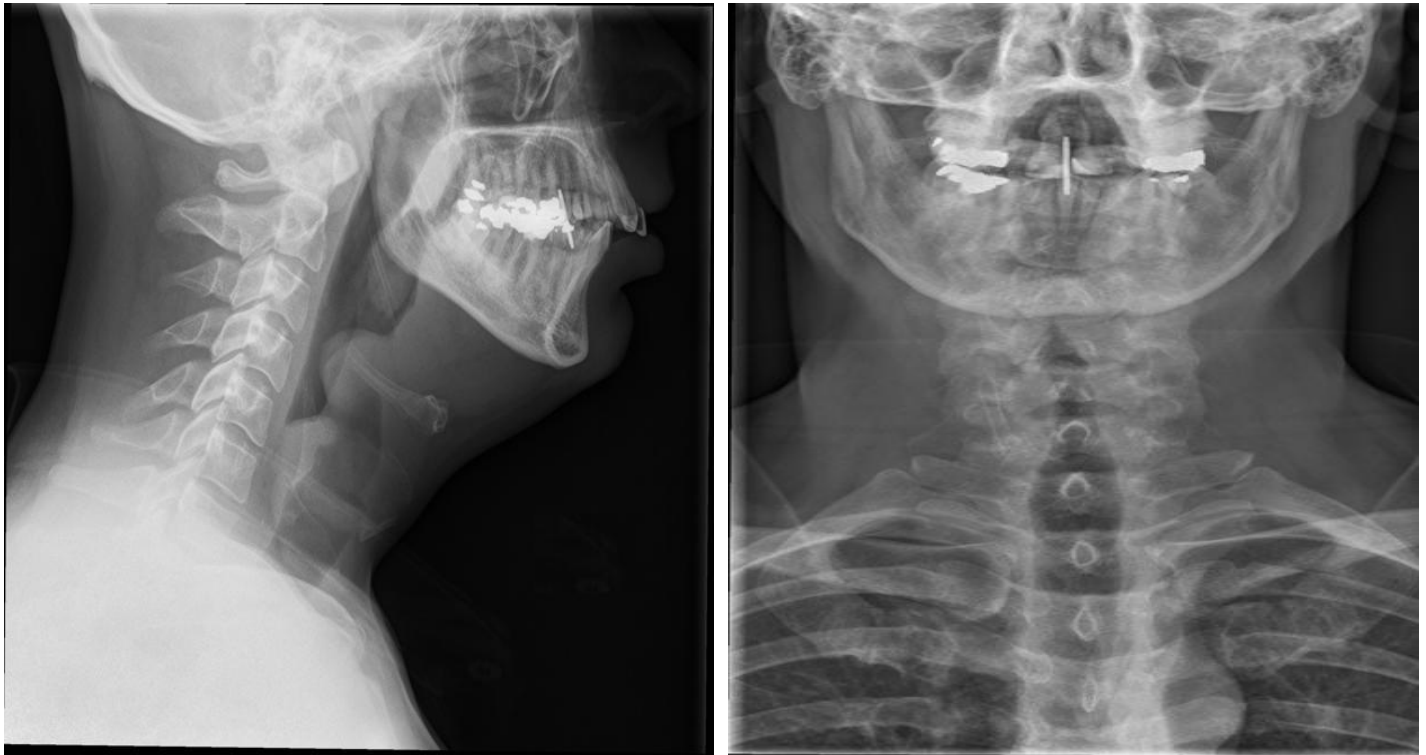


1. Comment on the position of the Nasogastric tube. (2 marks)

2. Name 4 features that you would consider the NG tube is in the optimal position. (4 marks)

Question 2 (6 marks)

A 60-year-old gentleman presented with sore throat and hoarseness of voice.



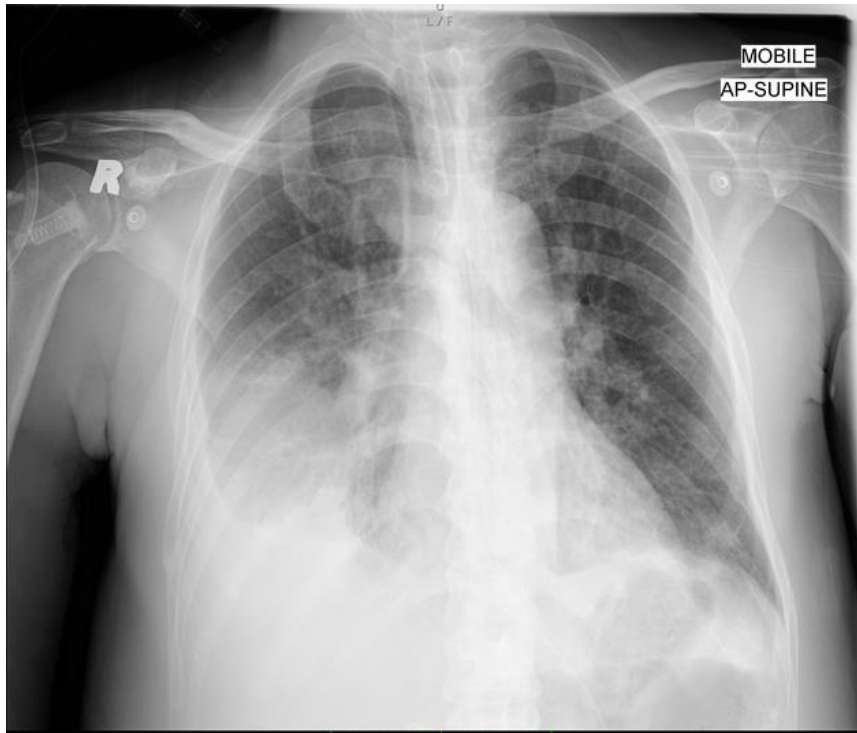1. Comment on the AP and lateral Neck XR. (2 marks)

2. What is the clinical diagnosis? (2 marks)

3. Name two complications associated with this condition. (2 marks)

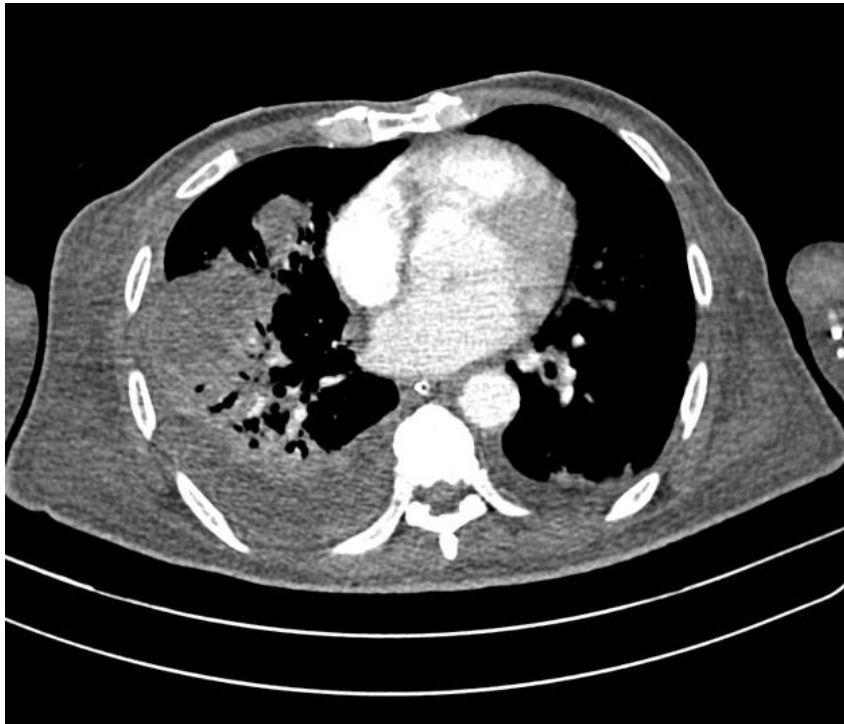
Question 3 (4 marks)

A 45-year-old male with history of DM and HT with fair control. Presented with dyspnoea and fever and admitted to medical ward due to desaturation.



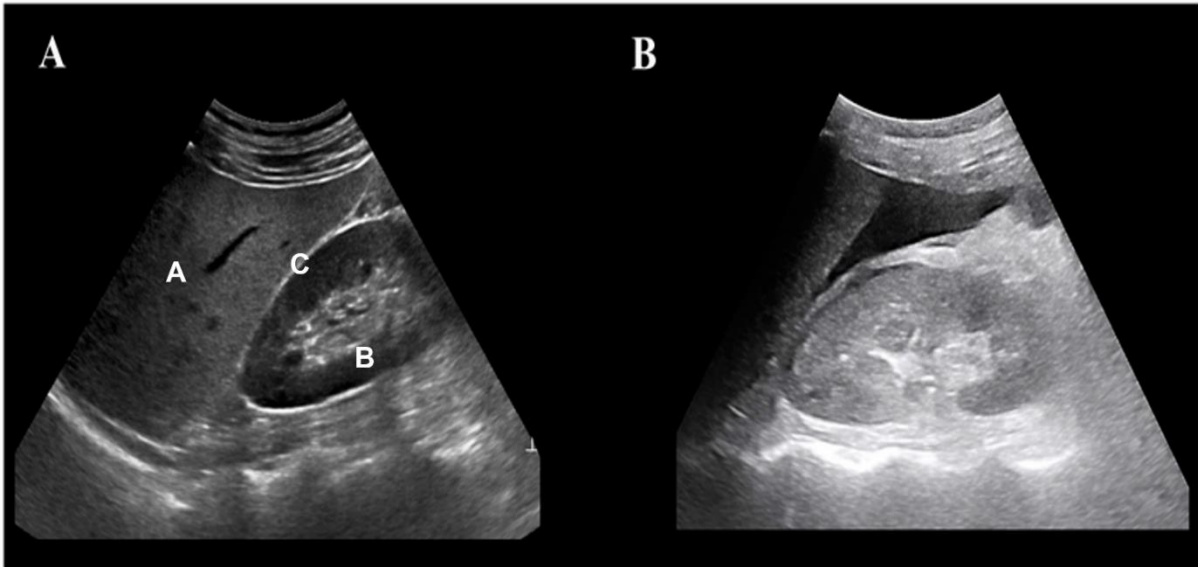
1. Comment on the CXR. (3 marks)

His condition was deteriorating with septic shock and a CT thorax was done.



2. What is the most likely clinical diagnosis? (1 mark)

Question 4 (8 marks)



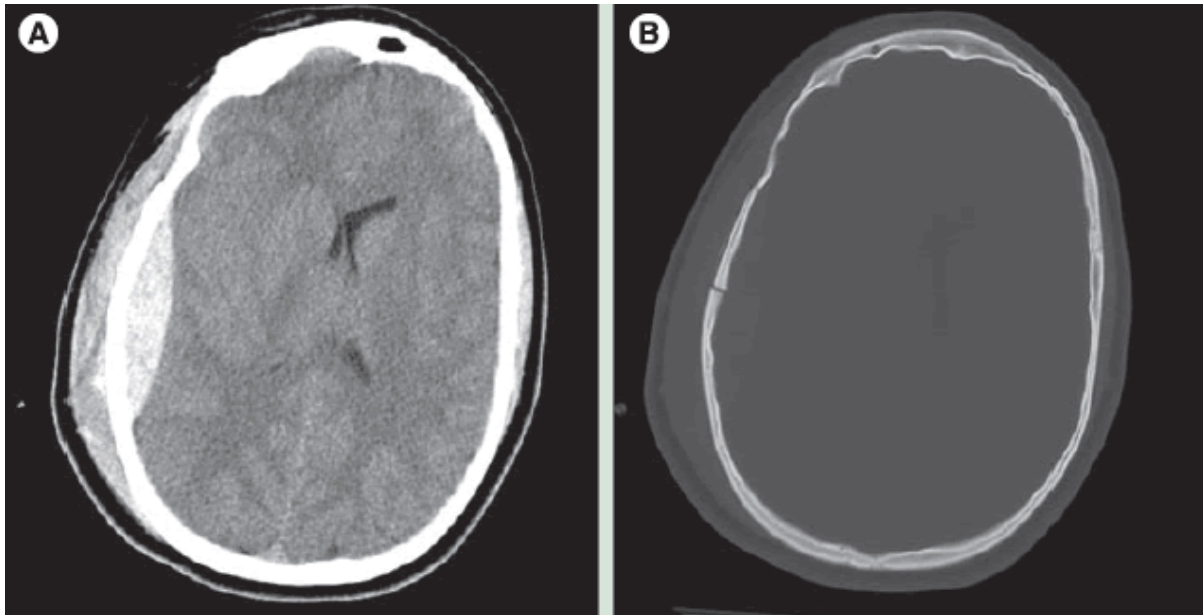
1. Name the structure A-C. (3 marks)

2. Comment on the USG findings in Fig B. (2 marks)

3. Name 3 differential diagnosis that will give rise to this USG finding. (3 marks)

Question 5 (6 marks)

A 70 year old lady presented with a fall and complained of dizziness.



1. Comment on the CT brain **A** (2 marks) and **B** (2 marks).

2. Name one intervention for this condition when it becomes acute and symptomatic. (2 marks)

----- END OF PAPER-----