

Candidate No: _____



The Hong Kong College of Anaesthesiologists

Final Fellowship Examinations

Paper II – Radiology (1 - 4)

12 August 2024 (Monday)

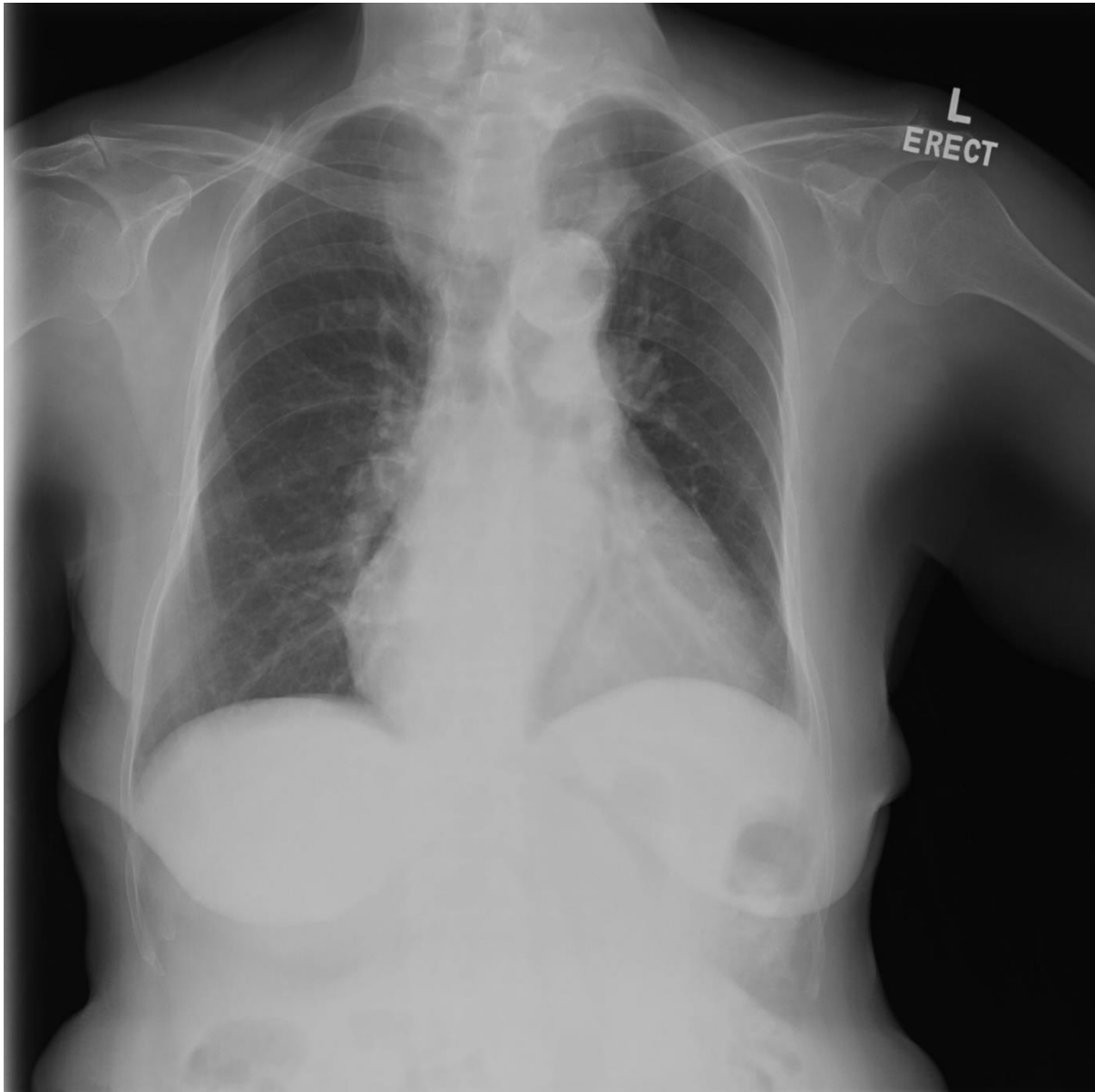
12:40 – 12:50 hours

Instructions:

- a. This is a question-answer book. Please write your answers in the space provided.
- b. Write your candidate number on the first page of the answer book.
- c. Use ink or ball-point pen.
- d. There are 4 questions in this paper, each with multiple parts.
- e. Answer **ALL** questions.
- f. For questions with multiple parts, allocation of marks is indicated in the brackets.

Question 1 (2 marks)

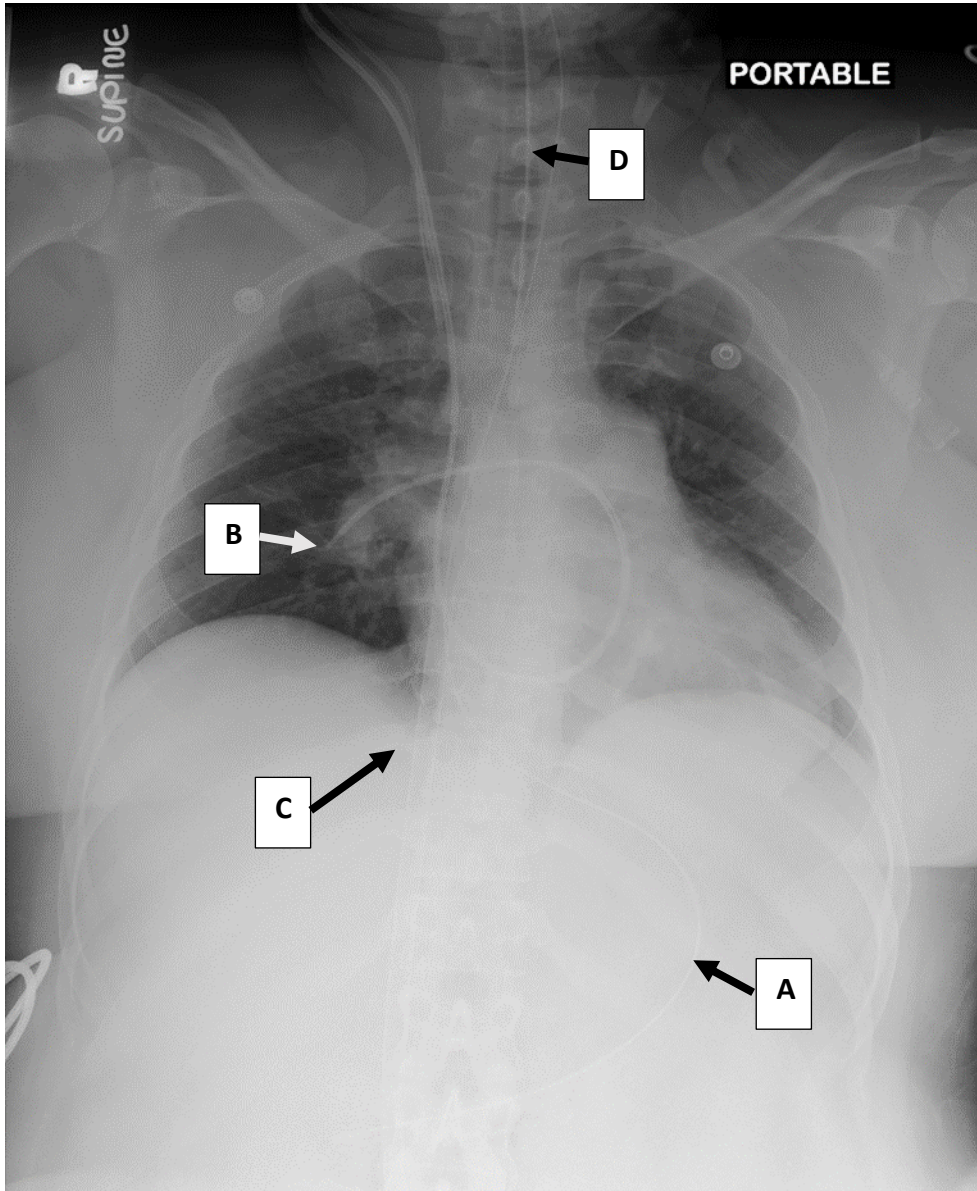
In the pre-anaesthetic assessment in the ward, you review the CXR of a 45-year-old woman who will have her urgent laparoscopic appendicectomy.



List two abnormalities (2 marks)

Question 2 (3 marks)

You review the CXR of a 35-year-old woman who had a high-risk Caesarean section performed for her peripartum cardiomyopathy.

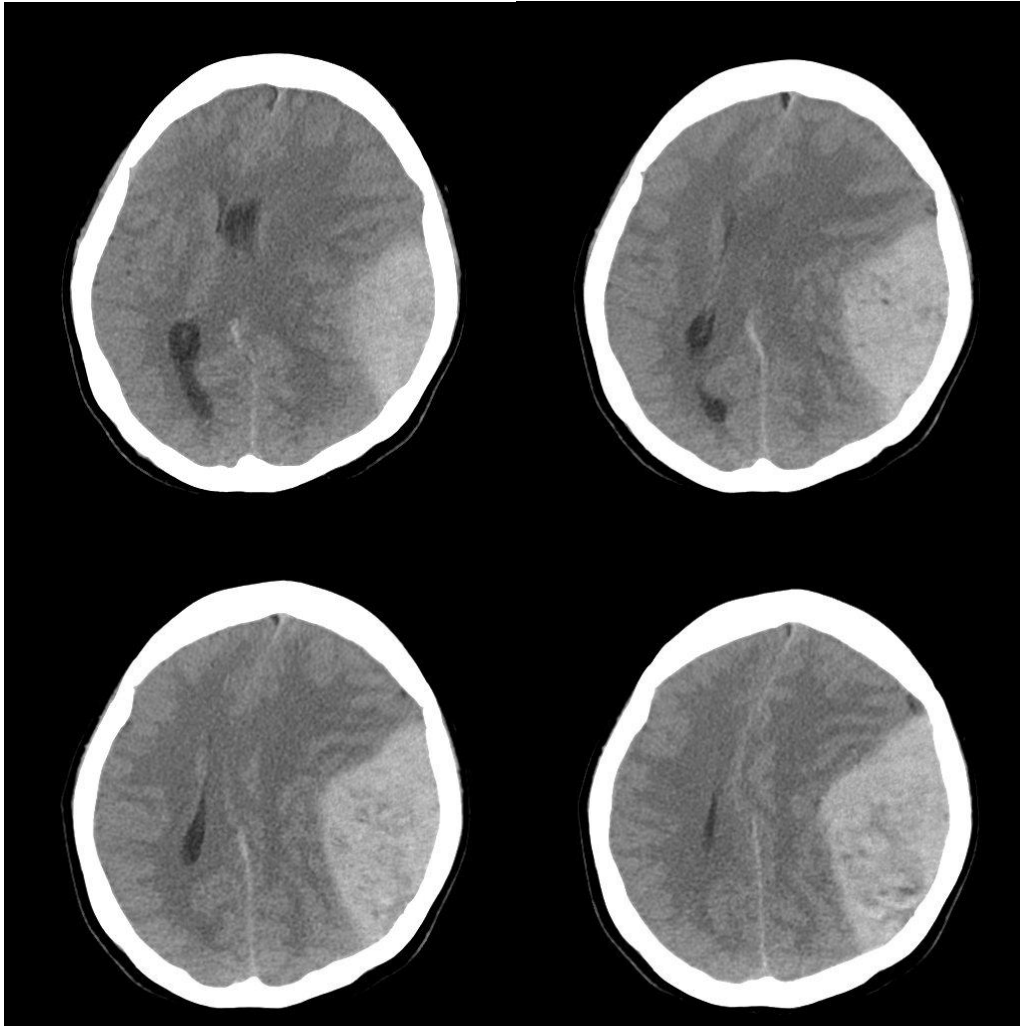


A. What is device C (1 mark)?

B. List 4 radiologic features indicating correct placement of device A (2 marks).

Question 3 (1 mark)

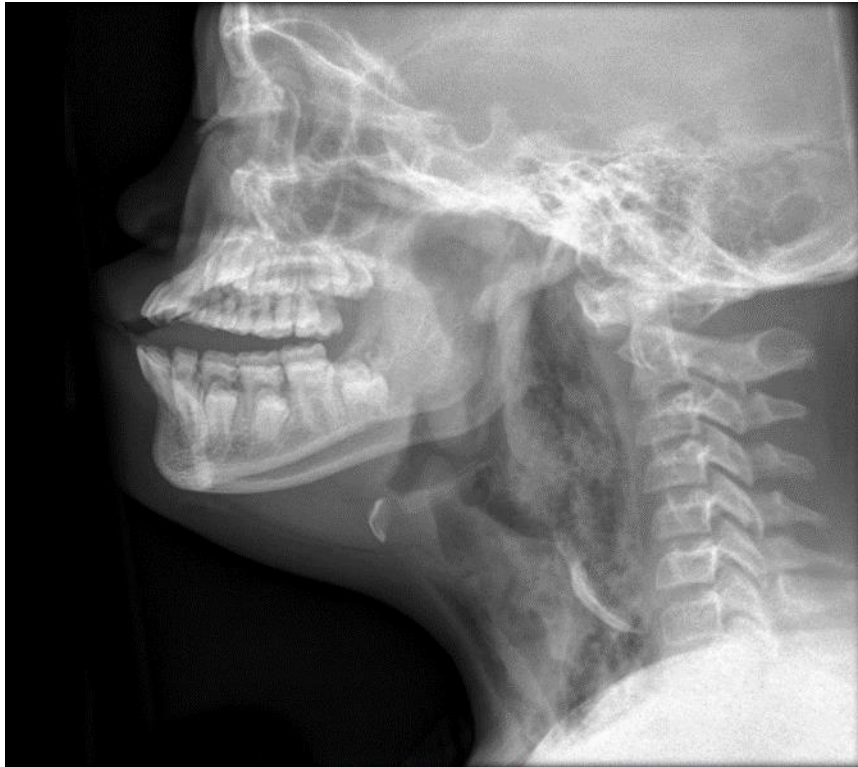
You review the plain CT brain of a 65-year-old woman who is not booked for an emergency craniotomy.



A. Name 2 abnormalities (1 mark).

Question 4 (2 marks)

A 40-year-old man complaint of swallowing difficulty and admitted to the Emergency Department for shortness of breath. The lateral neck X ray was shown below.



A. Name 2 abnormalities (2 marks).

----- END OF PAPER-----